

Physician to Physician: Case of the Month

Severe flatfoot with dislocation in a diabetic successfully reconstructed.

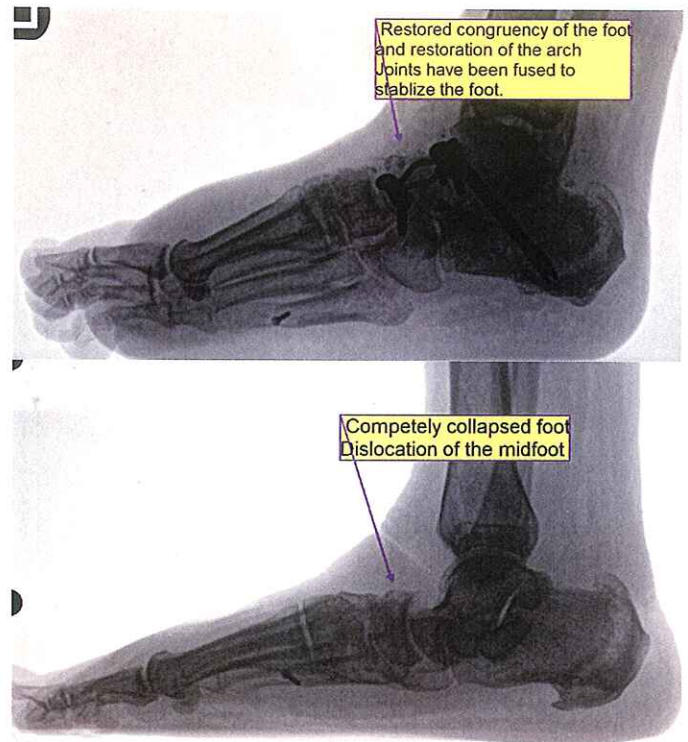
September 2014

Dear Physician,

This month I would like to share a very interesting case. When I first saw this patient, her left foot was swollen, painful, and she had very limited ability to walk even a few steps. Her foot had collapsed, with dislocation in the midfoot. The patient was a smoker, and had diabetes as well as neuropathy in her feet. This put her at great risk for Charcot joint disorder, which is where the foot completely collapses with fractures as a result of numbness in the feet. Unfortunately, this condition can quite frequently lead to amputation.

This patient was treated by applying a compression cast for a few weeks to get the swelling down. Once the swelling was down and we verified her circulation was okay, her blood sugar was well-controlled and she quit smoking, the patient was able undergo surgery to correct this very serious problem.

You can see in the Before and After photos to the right that the foot was stabilized and the arch restored.



If you have patients who suffer from flatfoot dislocation, please consider sending them our way. I would love to be able to help your patients restore their active lifestyles.

Yours in good health,

www.SilvesterFootClinic.com

409 N Bryant Street - Pleasanton, TX 78064 Phone 830-569-3338 Fax 830-569-6833
Next Step Foot & Ankle Clinic: Your NEXT STEP for Healthy Feet.