



Case of the Month

Ankle Instability

July 2015

Dear Physician,

Thank you very much for your referrals to our office. We love helping your patients restore their active lifestyles. This month's case concerns ankle instability. Happy Reading!

The problem:

We had a young lady come into the Next Step Foot & Ankle Clinic a few months ago who is quite active in sports in high school. She incurred multiple ankle sprains which had been treated with stretches, ice and Ace wraps and early return to activity. Her ankle continued to bother her and also she noted that she was quite prone to additional ankle sprains. Additionally, going downstairs was a real concern for her because she felt like she was going to twist her ankle. Sometimes when walking, she would step on a small pebble and roll her ankle.

The treatment:

This patient was placed in an ankle brace for a while to aid in balance and stability but no real resolution of her symptoms occurred. Dr. Silvester was able to do a range of motion study to evaluate the stability of her lateral ankle joint. She had a significant laxity of her lateral collateral ankle ligaments (loose ligaments).

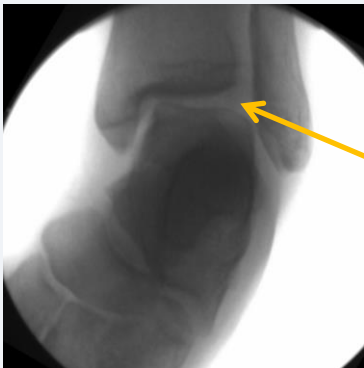The Long term solution:

Long-term, the patient needed modified Bronstrom Ankle Repair Surgery to repair these ligaments. After about 2 months of recovery, she returned to normal activities (including high school sports) supported by an ankle brace for a few months. She is very happy with her ankle now, it is much more stable.

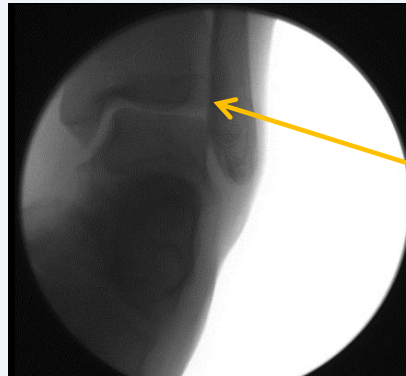
Yours in Good Health,

Darren J. Silvester, DPM

If you have patients who have ankle instability, please don't hesitate to refer your patient to us, call 830.569.3338. If you would like to learn more, call Stephanie to schedule a lunch and learn.



On the left:
Pre-op stress
x-ray image
with talar tilt
of about 15
degrees.



On the left: Post-op
stress x-ray image
with NO talar tilt.